

A rare case after hypospadias repair: Urethral diverticulum with stones

Pari Khalilova¹, Merve Bulbul¹, Bilgesu Arıkan Ergün², Seda Kaynak Sahap², Ergun Ergun¹, Murat Cakmak¹

Urethral stones are extremely rare in the pediatric population, accounting for only approximately 0.3% of all urinary tract calculi in children.^[1,2] These stones are typically symptomatic, and patients may present with acute complaints such as dysuria, weak urinary stream, urinary retention, or perineal pain. In some instances, however, urethral stones may be incidentally discovered during imaging studies performed for unrelated reasons or during urological evaluation prompted by other symptoms.^[1,3] The pathogenesis of urethral calculi may involve either the downward migration of stones from the upper urinary tract (renal or vesical origin) or de novo formation within the urethra, often facilitated by local anatomical or pathological abnormalities.^[4,5] Known predisposing factors include urethral strictures, diverticula, chronic infection, prior instrumentation, or the presence of foreign bodies, all of which may promote urinary stasis and act as a nidus for stone formation.

In this article, we present a rare case of urethral diverticulum with stones in a child who was operated due to penoscrotal hypospadias.

Received: September 22, 2024
Accepted: December 23, 2024
Published online: August 11, 2025


Correspondence: Pari Khalilova, MD.
E-mail: dr.parikhalilova@gmail.com

¹Department of Pediatric Surgery, Ankara University Faculty of Medicine, Ankara, Türkiye

²Department of Pediatric Radiology, Ankara University Faculty of Medicine, Ankara, Türkiye

Citation:

Khalilova P, Bulbul M, Arıkan Ergün B, Kaynak Sahap S, Ergun E, Cakmak M. A rare case after hypospadias repair: Urethral diverticulum with stones. Turkish J Ped Surg 2025;39(2):96-98. doi: 10.62114/JTAPS.2025.75.

 This is an open access article licensed under the Creative Commons Attribution-NonCommercial 4.0 International License (CC BY-NC 4.0). <https://creativecommons.org/licenses/by-nc/4.0/>

Abstract

Urethral stones are rare in children, accounting for only 0.3% of all pediatric urinary stones. An eight-year-old boy was admitted with a history of penoscrotal hypospadias repair in whom urethral diverticulum with stones was developed. After a prolonged treatment process, the patient did not attend follow-up visits for nearly five years, as there were no recurring complaints. The patient initially presented with meatal stricture and a scrotal ultrasound revealed a calcified stone. Surgical removal was performed with excision of the diverticulum and two-layer urethral repair. Postoperative crystallographic analysis result was reported as struvite. In conclusion, urethral stones, although uncommon, may develop in children with conditions such as hypospadias that promote urinary stasis. Surgical intervention is crucial to prevent recurrence, and stone analysis helps guide future treatment.

Keywords: Children, diverticulum, hypospadias, stone.

CASE REPORT

An eight-year-old boy presented to our clinic with complaints of painful urination, a thin urine stream, and spraying during urination. The patient underwent surgery for penoscrotal hypospadias at an external center six years ago, followed by fistula repair at the mid-penile level two years later. After surgery, due to the absence of urinary output through the catheter, he was followed with a suprapubic catheter for two weeks. Urethral dilatation was performed for five times. The patient reported no clinical issues at home and did not attend follow-up visits. In his medical history, there were no urinary tract infection or related symptoms. On physical examination, a firm mass was observed at the penoscrotal level, and a scrotal ultrasound revealed a roughly 9-mm in diameter coarse calcification focus superficially located in the midline, inferior to the penis. Urinary

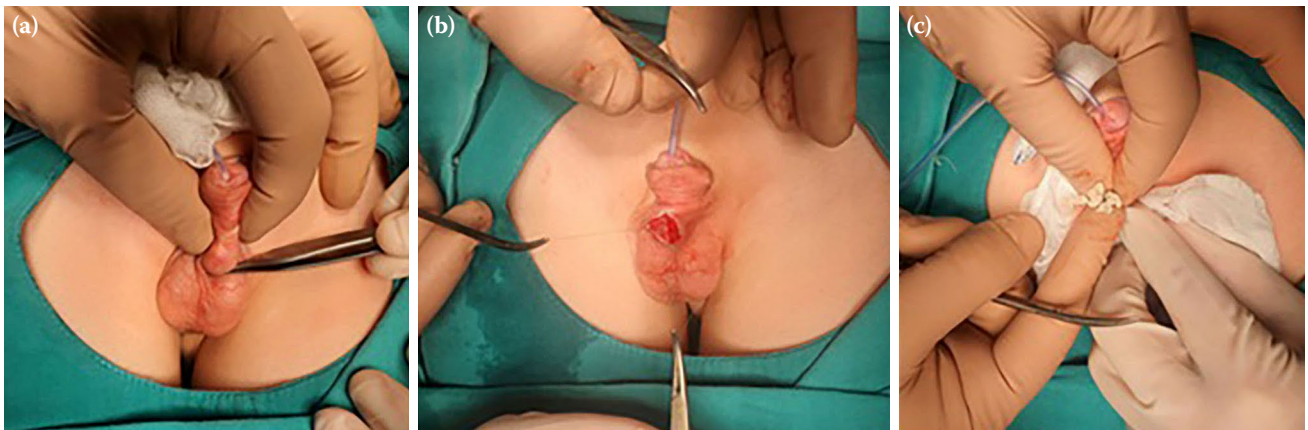


Figure 1. Intraoperative images: (a) External view of the diverticulum; (b) Appearance of the urethral mucosa inside the diverticulum; (c) Stones.

ultrasonography showed normal findings apart from those described.

The patient underwent surgery, and a 1-cm longitudinal incision was made over the palpable paraurethral stone. The skin and subcutaneous tissue over the stone were incised, and the stone was excised. Urethral mucosa was observed inside the stone cavity, and a pinpoint connection with the urethra was identified by opening it circumferentially (Figure 1). Excess mucosa was removed, and a two-layer urethral repair was performed right over the fistula. Dartos tissue was brought over, and two subcutaneous tissues

were dissected and sutured in a crossed manner (vest over pants). The skin incision was closed with interrupted stitches. During surgery, 7/0 PDS was used. Crystallographic analysis result was reported as struvite (Figure 2). A written informed consent was obtained from the parents and/or legal guardians of the patient.

DISCUSSION

Urinary system stones are less common in children than in adults. There is a pediatric stone belt extending from the Far East through the Philippines, Thailand, the Middle East including Pakistan and Iran, reaching up to Türkiye.^[2,6,7]

Urinary stasis predisposes to infection, crystallization, and stone formation. This stasis, resulting from insufficient collapsibility of the urethra, is more commonly observed in patients with hypospadias. Stone development is seen in 4 to 10% of patients with urethral diverticula.^[8] When the main urethral lumen is not completely obstructed by stones in the diverticulum, the emergence of acute urinary retention is rare. Clinical symptoms such as urinary tract infections due to urine accumulation, pain, visible swelling, and hardness on palpation can be observed.^[1,3,9,10]

The removal of stones within the main urethral lumen through cystoscopy with forceps or laser ablation has been demonstrated in the literature.^[11,12] To prevent recurrence and remove stones within the diverticulum, it is necessary



Figure 2. Crystallographic analysis result reported as struvite stones.

to excise the diverticulum and completely sever its connection with the main lumen. Due to the patient's history of previous urethral surgery, we decided not to proceed with this method, considering the potential need for excision.

While the composition of most urethral stones in developing countries is reported to be struvite and uric acid, the most common results of stone analyses in developed countries are calcium oxalate and cystine.^[2] Investigating the stone content is necessary for etiology and preventing recurrence. Appropriate treatment or prophylactic antibiotics can be options for patients with a familial predisposition. In our case, postoperative crystallographic analysis identified the stone as struvite.

Considering cases of acute urinary retention due to stones originating from the proximal urinary tract, patients should always be investigated for upper urinary system stones, as well.^[3,9]

In conclusion, although urethral stones are extremely rare in children, such stones may develop after complicated hypospadias repair. A urethral diverticulum with a narrow neck exposing long-term urinary stasis or concurrent infections may result in stone formation, particularly in patients with delayed diagnosis. Therefore, urolithiasis should be kept in mind in children with acute urine retention or those undergoing complicated hypospadias repair, even in areas which are not endemic.

Data Sharing Statement: The data that support the findings of this study are available from the corresponding author upon reasonable request.

Author Contributions: Study idea/concept, critical review: P.K., M.C.; Design and writing the article: E.E., B.A.E.; Data collection and/or processing/materials: S.K.S., M.B.; Literature review: E.E., M.C.; Control/supervision: P.K.

Conflict of Interest: The authors declared no conflicts of interest with respect to the authorship and/or publication of this article.

Funding: The authors received no financial support for the research and/or authorship of this article.

REFERENCES

1. Mohanty D, Garg P, Jain B, Bhatt S. Male urethral diverticulum having multiple stones. *Ann Med Health Sci Res* 2014;4 (Suppl 1):S53-5. doi: 10.4103/2141-9248.131719.
2. Verit A, Savas M, Ciftci H, Unal D, Yeni E, Kaya M. Outcomes of urethral calculi patients in an endemic region and an undiagnosed primary fossa navicularis calculus. *Urol Res* 2006;34:37-40. doi: 10.1007/s00240-005-0008-2.
3. Al-Hajjaj M, Tawosh A, Adam Bary AO, Riyadh Alabdaly A, Osama Altayep R. A rare cause of urinary retention in a child: A case report. *Urol Case Rep* 2023;46:102328. doi: 10.1016/j.eucr.2023.102328.
4. Subbarao P, Lal R, Bhatnagar V, Mitra DK. Multiple urethral calculi in children: Report of two cases. *Surg Today* 1998;28:1210-2. doi: 10.1007/s005950050317.
5. Giannakis I, Kaltsas A, Takenaka A, Sofikitis N, Zachariou A. Urethral diverticulum with stone formation in an adult male after hypospadias repair: A case presentation. *Urol Case Rep* 2023;51:102624. doi: 10.1016/j.eucr.2023.102624.
6. Menon M, Martin IR. Urinary lithiasis: etiology, diagnosis and medical management. In: Walsh PC, Retik AB, Vaughan ED, Wein AJ, editors. *Campbell's urology*. 8th ed. Vol 4. Philadelphia: W.B. Saunders; 2002. p. 3288-3289.
7. Alshubaili AM, Alotaibi AF, Alsaleh KA, Almogarri AI, Alanizi AA, Alsaif SS, et al. The prevalence of nephrolithiasis and associated risk factors among the population of the Riyadh Province, Saudi Arabia. *Cureus* 2024;16:e55870. doi: 10.7759/cureus.55870.
8. Gonzalvo Pérez V, Botella Almodovar R, Canto Faubel E, Gasso Matoses M, Llopis Guixot B, Polo Peris A. Urethral diverticulum complicated with giant lithiasis. *Actas Urol Esp* 1998;22:250-2.
9. Balarabe HS, Jeannot BM, Kibansha HM, Isaac E, Kiswezi A. Urethral calculus with a recurrent acute urinary retention in a male child aged 11 years: A case report. *Radiol Case Rep* 2023;18:4191-4. doi: 10.1016/j.radcr.2023.08.086.
10. Kita N, Nagao Y, Nabeshima Y, Yamane I, Hirata M, Hatakeyama K. Formation of a calcium oxalate urethral stone in a 3-year-old boy due to hypocitraturia. *IJU Case Rep* 2020;3:49-52. doi: 10.1002/iju5.12140.
11. Walker BR, Hamilton BD. Urethral calculi managed with transurethral Holmium laser ablation. *J Pediatr Surg* 2001;36:E16. doi: 10.1053/jpsu.2001.26398.
12. Kamal BA, Anikwe RM, Darawani H, Hashish M, Taha SA. Urethral calculi: Presentation and management. *BJU Int* 2004;93:549-52. doi: 10.1111/j.1464-410x.2003.04660.x.