

# Can a frenuloplasty performed during circumcision lead to meatal stenosis?

Şenay Kurtuluş 

Circumcision is the surgical removal of the foreskin which covers the glans penis and the external urethral orifice. It has been reported that circumcision, particularly when performed before the age of one year, reduces the risk of urinary tract infection in children and the future risk of penile cancer development, and it also plays an important role in the prevention of sexually transmitted diseases. Some authors have argued that it is unnecessary and even harmful, as it can lead to serious complications.<sup>[1-4]</sup>


Meatal stenosis (MS) is a condition where the urethral meatus narrows. It is considered a potential long-term complication of male circumcision. Meta-analyses have demonstrated that while the prevalence of MS is higher in circumcised boys compared to uncircumcised boys, the actual risk of developing MS after circumcision is low at 0.7%.<sup>[5]</sup> Although often asymptomatic, in the presence of MS, complaints such as high-pressure and fine-calibrated urination, and painful and prolonged urination with delayed onset may occur after toilet training. Although extremely rare, cases of vesicoureteral reflux and hydronephrosis secondary to MS have also been reported.<sup>[6,7]</sup>

Received: August 19, 2024  
Accepted: November 01, 2024  
Published online: December 18, 2024  
Correspondence: Şenay Kurtuluş, MD.  
E-mail: senaykurtulus@yahoo.com

Department of Pediatric Surgery, Çanakkale Onsekiz Mart University Health Practice and Research Hospital, Çanakkale, Türkiye

## Citation:

Kurtuluş Ş. Can a frenuloplasty performed during circumcision lead to meatal stenosis? Turkish J Ped Surg 2024;38(3):97-102. Doi: 10.62114/JTAPS.2024.63.

 This is an open access article licensed under the Creative Commons Attribution-NonCommercial 4.0 International License (CC BY-NC 4.0). <https://creativecommons.org/licenses/by-nc/4.0/>

## Abstract

**Objectives:** In this study, we aimed to investigate the role of frenuloplasty in developing meatal stenosis (MS) in boys who underwent frenuloplasty and those whose frenulum was preserved.

**Patients and methods:** Between June 2022 and July 2023, medical data of a total of 308 male patients who were circumcised using a guillotine or squeezing technique with an Alisklamp were retrospectively analyzed. The patients were divided into two groups based on whether frenuloplasty was performed during circumcision. Group 1 (frenuloplasty with circumcision, n=153 [mean age: 62.6±39.0 months; range, 2 to 132 months]) and Group 2 (frenulum preserved, n=155 [mean age: 6.7±3.9 months; range, 2 to 22 months]) were both evaluated for the development of complications, including MS after circumcision.

**Results:** Wound infection was observed in one patient in Group 1 and post-circumcision bleeding and secondary phimosis were observed in two patients in Group 2. When the parents were questioned about the urination habits of their children in the outpatient clinic follow-ups, there were no complaints of decreased urine thickness, prolonged urination, or difficulty in starting to urinate. In the outpatient follow-up at one week, one month, and six months, the external urethral meatus was evaluated as normal. In the external genital examinations performed at one week, one month, and six months after circumcision, the external urethral meatus was evaluated as normal in all patients.

**Conclusion:** Meatal stenosis is not a common complication of circumcision, and frenuloplasty is not a risk factor for developing MS.

**Keywords:** Alisklamp, circumcision; frenuloplasty, meatal stenosis.

The cause of MS development after circumcision is unclear; however, some hypothetical mechanisms have been proposed for the role of circumcision in the etiology. It has been suggested that mechanical and chemical trauma to the glans and external urethral meatus, which remain unprotected after neonatal circumcision, results in stenosis due to epithelial damage to the glans.<sup>[8,9]</sup>

In circumcision techniques that damage the frenular branches of the dorsal penile artery, ischemia of the distal urethra and meatus may occur, thereby leading to the development of MS. Frenular artery-sparing circumcision techniques support this theory.<sup>[10,11]</sup> On the other hand, some authors have proposed that frenuloplasty during circumcision may increase the risk of developing MS in school-aged boys.<sup>[7,12]</sup> Frenuloplasty is performed during circumcision, sometimes when the integrity of the frenulum is disrupted and sometimes to obtain a better cosmetic result. In the present study, we aimed to investigate the role of frenuloplasty in the development of MS in patients who applied for circumcision in our clinic and underwent frenuloplasty, and in those in whom the frenulum was preserved.

## PATIENTS AND METHODS

This single-center, retrospective study was conducted at Department of Pediatric Surgery, Çanakkale Onsekiz Mart University Health Practice and Research Hospital between June 2022 and July 2023. Medical data of a total of 308 male patients who were circumcised in our center were analyzed. Circumcision was performed in all patients for religious or traditional reasons. The patients were divided into two groups according to whether frenuloplasty was performed or the frenulum was preserved during circumcision: Group 1 (frenuloplasty with circumcision, n=153 [mean age: 62.6±39.0 months; range, 2 to 132 months]), and Group 2 (frenulum preserved, n=155 [mean age: 6.7±3.9 months; range, 2 to 22 months]). All circumcisions were performed by a single experienced surgeon. The patients were circumcised by the application of two circumcision methods, including guillotine circumcision followed by frenuloplasty and the squeezing technique with plastic Alisklamp. Those with penile anomalies, including hypospadias, epispadias, chordee or previous history of circumcision were excluded from the study. A written informed consent was obtained from the parents and/or legal guardians of the patients. The study protocol was approved by the Çanakkale 18 Mart University Clinical Research Ethics Committee (date: 20.09.2023, no: 2023/12-02). The study was conducted in accordance with the principles of the Declaration of Helsinki.

All patients were followed a minimum of six months after circumcision to screen for late complications MS. During follow-up, we informed parents of MS symptoms such as difficulty initiating and maintaining urine flow and directing the urine to the toilet, urination that takes a long time with a thin urine stream or decreased urinary calibre. All patients were evaluated as if there was an apparent narrowing of the meatal opening in the meatus.

### Guillotine circumcision with frenuloplasty

We performed a guillotine circumcision and frenuloplasty in Group 1. All patients were circumcised under general anesthesia, and a dorsal penile nerve block was performed with 0.2 mL/kg 0.25% bupivacaine infiltration with a 26-gauge needle tip at the penis root at 10 and 2 o'clock. First, the foreskin was pulled down, and any adhesions between it and the glans were removed. The foreskin was, then, held in the 12 and 6 o'clock positions. A flat hemostat was placed on the foreskin, obliquely in favor of the ventral, in the projection of the sulcus just below the glans penis. The foreskin was slid over the glans, pulled up, and clamped, ensuring that the glans remained under the hemostat. The prepuce was cut off above the clamp, and the inner layer was trimmed circumferentially, leaving a margin of approximately 1 cm on all sides (Figure 1).

After the mucosa was shortened, the excess mucosa in the frenulum was removed by making a V-shaped excision of Burow's triangles. Single large or multiple smaller triangles were removed from any position, proximal, central, or distal portion of the longer side of the wound, depending on the clinical circumstances along the longer side, and the lengths of the wound edges are equalized. Frenuloplasty was completed by approximating the mucosa in the inverted "V"-shaped area created in the frenulum (Figure 2).

The circumcision was, then, completed by using interrupted absorbable sutures, For intraoperative bleeding control, reusable medical and optical bipolar forceps with Valleylab Force FX™ Electrosurgical Generator (Covidien, Mansfield, MA, USA) with bipolar diathermy were used. After the procedure, the wound was dressed with gauze and coated with mupirocin ointment. The patients were discharged on the same day with simple analgesia. The dressing was left intact, until it fell off. The patients were

scheduled for follow-up at one week and three months.

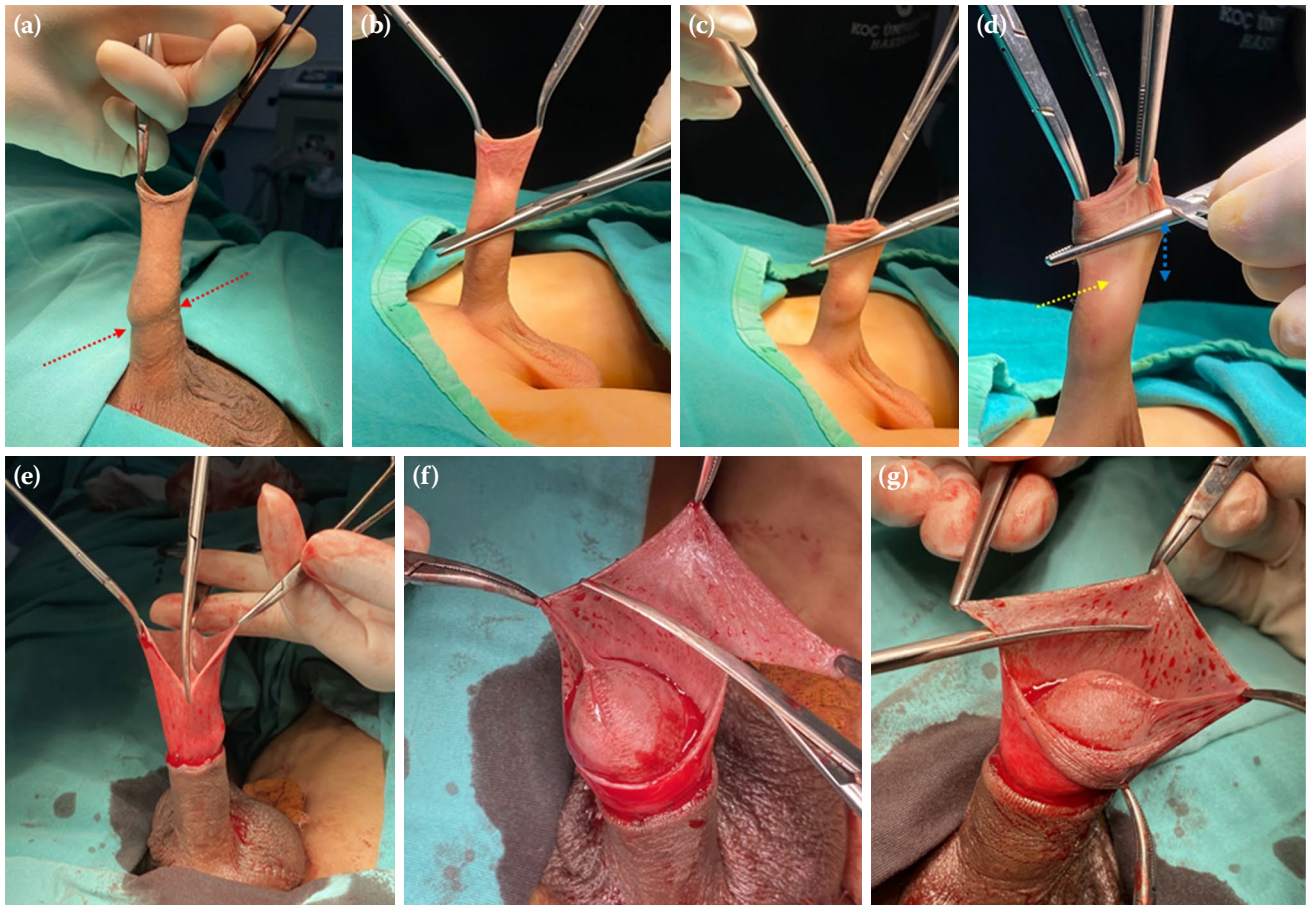
### Squeezing circumcision with plastic Alisklamp

After the dorsal penile nerve block mentioned above was applied. Alisklamp, available in various sizes for all ages and consisting of a separate inner tube and an outer ring with locking arms at the side, was applied to the patients. Initially, the foreskin was retracted completely. When the normal glans were exposed, the inner tube of the Alisklamp was placed over the glans, and the retracted foreskin was pulled over this tube. Then, the outer ring was

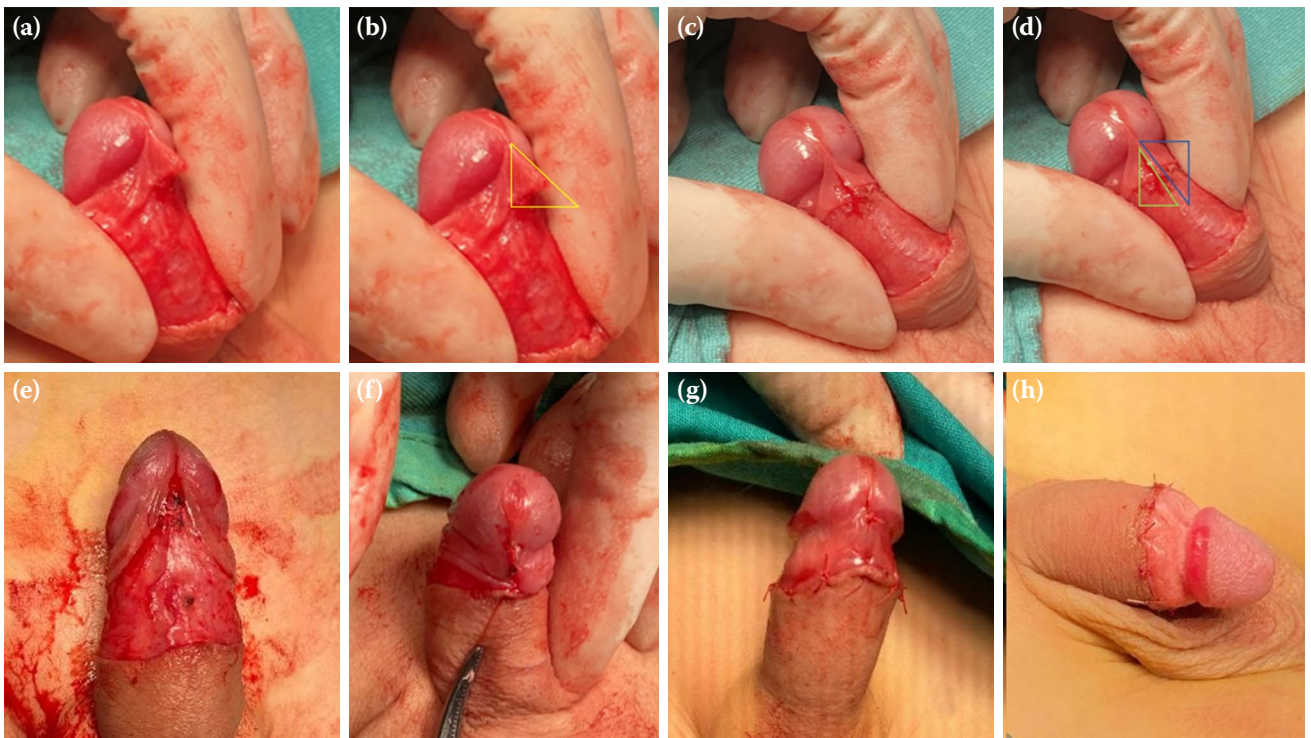
placed over the foreskin. Once enough foreskin was pulled, the clamp was locked, and at the distal to the outer ring, prepuce was excised (Figure 3). Dressing was not necessary, and the clamp was removed after 48 h.

### Statistical analysis

Statistical analysis was performed using the SPSS version 13.0 software (SPSS Inc., Chicago, IL, USA). Descriptive data were presented in mean  $\pm$  standard deviation (SD), median (min-max) or number and frequency, where applicable. The normality of the distribution of variables was checked using the Kolmogorov–Smirnov and Shapiro-Wilk test.

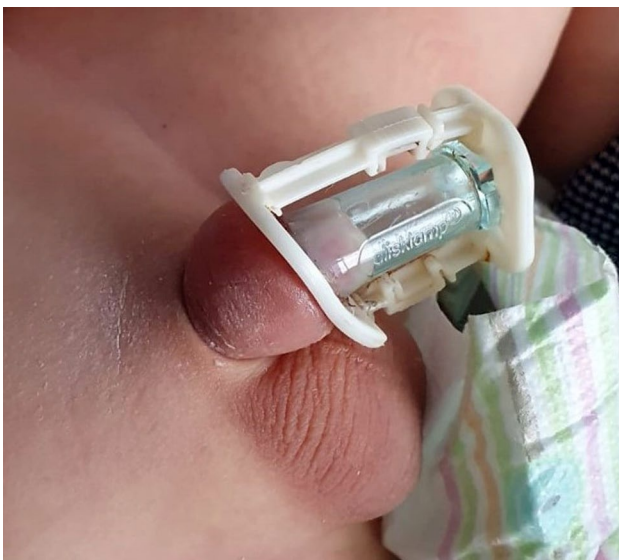

**Figure 1.** The guillotine circumcision technique. (a) Red arrows indicate the line where the glandular sulcus is observed, the prepuce is grasped with two hemostats and stretched strongly. (b) A flat hemostat is placed on the oblique sulcus just below the glans penis. (c, d) A flat clamp is slid over the glans, clamped, and the prepuce is cut above the clamp, the yellow arrow shows the distal part of the glans, and the blue arrow shows the safe distance between the clamp and the glans. (e-g) The inner leaf of the foreskin is cut in the dorsal midline from the free end to a maximum of 5-10 mm from the corona. Proceeding from this point, the circumferential incision is made laterally and circumferentially around the glans on each side until the frenulum is reached. The inner layer is trimmed all around, leaving a 5-10 mm margin.



**Figure 2.** Burow's Triangle/V Excision frenuloplasty technique. (a) Redundant excess mucosa following circumcision. (b-e) Single large (yellow triangle) or multiple darts are removed from the frenulum, and the inverted triangular tissue is excised from the frenulum (green and blue triangle). (f) Reconstruction of frenulum with interrupted 5-0 absorbable sutures and the mucosa is joined to the midline. (g, h) Completion of circumcision by combining the skin and mucosa.

The chi-square test was used to analyze differences between the groups. A  $p$  value of  $<0.05$  was considered statistically significant.



**Figure 3.** Squeezing circumcision with plastic Alisklamp.

## RESULTS

Demographic and baseline data of the patients are presented in Table 1. Of a total of 308 patients, there were 153 in Group 1 (49.7%) and 155 in Group 2 (50.3%). In Group 1, circumcision was performed together with herniography in seven patients (n=4 right, n=3 left, n=1 bilaterally) and orchiopexy in 21 patients (n=6 right, n=9 left, n=6 bilateral). Wound infection was observed in one patient in Group 1 ( $p=0.314$ ) and post-circumcision bleeding ( $p=0.084$ ) and secondary phimosis were observed in two patients in Group 2 ( $p=0.058$ ). In the post-circumcision control examinations, no stenosis was found in the external urethral meatus in either group. When the parents were questioned about the urination habits of their children in the outpatient clinic follow-ups, there were no complaints of decreased urine thickness, prolonged urination, or difficulty in starting to urinate and that they did not notice any changes before or after circumcision. In the outpatient follow-up at one week, one month, and six months, the external urethral meatus was evaluated

**TABLE 1**  
Demographic data and complications

	Group 1 (n=153)				Group 2 (n=155)				Total	<i>p</i>
	n	%	Mean±SD	Min-Max	n	%	Mean±SD	Min-Max	n	
Age (year)			62.6±39.0	2-132			6.68±3.89	2-22		0.000
Complication										
Infection	1	0.65			-	-			1	0.314
Bleeding	-	-			3	1.93			3	0.084
Meatal stenosis	-	-			-	-			-	
Secondary phimosis	1	0.65			6	3.8			7	0.058

SD: Standard deviation.

as normal. In the external genital examinations performed at one week, one month, and six months after circumcision, the external urethral meatus was evaluated as normal in all patients.

## DISCUSSION

Despite the controversy, circumcision, which is still one of the most common elective surgical procedures worldwide, is performed on almost every male in Türkiye for cultural or religious reasons. There are many traditional open techniques for circumcision, such as the dorsal slit, the sleeve, and the guillotine. Still, circumcision is also performed with the squeezing technique using devices such as Mogen and Gomco clamps, Smartklamp, Taraklamp, Alisklamp, or Plastibell.<sup>[13,14]</sup> The basic principle of circumcision is to achieve the best cosmetic result by minimizing complications, no matter what technique is used.<sup>[15]</sup>

Meatal stenosis is hypothesized to be a possible complication of male circumcision. It has been suggested that male circumcision or accompanying frenuloplasty may increase the risk of developing MS due to ischemia from frenular artery damage during circumcision.<sup>[5,11]</sup> The male urethra is unique, as it is a relatively long structure that passes through several compartments in the body and therefore, receives blood supply and innervation from a broad array of sources.<sup>[16]</sup> It receives blood supply from the inferior vesical artery, bulbourethral artery, and the internal pudendal artery. The superficial external pudendal artery provides the frenulum blood supply. In contrast, the dorsal and deep arteries of the penis that feed the penile urethra are branches of the internal pudendal artery.<sup>[17,18]</sup>

Although its pathophysiological hypotheses have not been fully elucidated, preserving the frenular artery during circumcision is advisable.<sup>[7,12,19]</sup> A study by Shenoy et al.<sup>[12]</sup> found that preserving the frenulum during circumcision in 42 patients prevented the development of MS. However, in our study, we did not find evidence of MS among 153 patients who underwent frenuloplasty with circumcision or in men whose frenulum was preserved. Therefore, currently, there is not enough evidence to suggest that the risk of MS may be higher in circumcised boys and young adult men.<sup>[5]</sup>

While some studies have shown that MS can be a possible complication of circumcision, there is currently insufficient evidence to establish a direct relationship between frenuloplasty and MS.<sup>[5,6,9]</sup> In a study conducted by Dayı et al.,<sup>[7]</sup> frenuloplasty during circumcision was found to increase the risk of developing MS in boys. However, the aforementioned study reported that the incidence of MS in circumcised cases without frenuloplasty was higher than reported in the literature. In our study, we did not find evidence of MS in men who underwent frenuloplasty with circumcision or whose frenulum was preserved, and in the literature, MS in circumcised men is extremely low and is not considered significant.<sup>[5]</sup>

Another theory is that circumcision may cause narrowing of the urethra due to irritation of the urethral mucosa caused by the removal of the prepuce, which is thought to protect the glans, particularly in infants.<sup>[20]</sup> However, it has also been shown that newborn circumcision is usually safe, and there is no risk of MS as long as the frenular artery is not damaged during the procedure.<sup>[10]</sup> In

our study, all 155 boys who underwent circumcision using an Alisklamp were still diapered. We did not observe any cases of post-circumcision MS in this group. Our results also do not support the hypothesized theories of chemical and mechanical trauma.<sup>[21]</sup>

We believe that MS is an uncommon complication of either circumcision or frenuloplasty. Voiding is a physiological event and the external urethral meatus cannot be exposed to trauma due to urination. In addition, considering the anatomical position of the penis and the placement of the diaper in diapered infants, it cannot be speculated that the penis is in direct contact with the diaper.

In conclusion, based on our study results, there is no evidence to suggest that frenuloplasty during circumcision in boys increases the risk of developing MS. Therefore, MS is not a common complication of circumcision, and frenuloplasty during the procedure is not a risk factor for developing MS. However, further multi-center, large-scale, prospective studies are needed to confirm these results.

**Data Sharing Statement:** The data that support the findings of this study are available from the corresponding author upon reasonable request.

**Conflict of Interest:** The author declared no conflicts of interest with respect to the authorship and/or publication of this article.

**Funding:** The author received no financial support for the research and/or authorship of this article.

## REFERENCES

1. JS E. Congenital anomalies of the genitalia. In: Walsh PC, Retik AB, Vaughan ED, Wein AJ, editors. *Campbell's urology*. Vol. 2. Philadelphia: W.B. Saunders; 1998. p. 2120-2143.
2. Chan JY, Khondker A, Lee MJ, Kim JK, Chancy M, Chua ME, et al. The role of circumcision in preventing urinary tract infections in children with antenatal hydronephrosis: Systematic review and meta-analysis. *J Pediatr Urol* 2023;19:766-77. doi: 10.1016/j.jpuro.2023.07.017.
3. Gray RH, Kigozi G, Serwadda D, Makumbi F, Watya S, Nalugoda F, et al. Male circumcision for HIV prevention in men in Rakai, Uganda: A randomised trial. *Lancet* 2007;369:657-66. doi: 10.1016/S0140-6736(07)60313-4.
4. Circumcision AA of PTF on. Circumcision policy statement. *Pediatr* 2012;130:585-586. doi:10.1542/peds.2012-1989.
5. Morris BJ, Krieger JN. Does circumcision increase meatal stenosis risk? A systematic review and meta-analysis. *Urology* 2017;110:16-26. doi: 10.1016/j.urology.2017.07.027.
6. Godley SP, Sturm RM, Durbin-Johnson B, Kurzrock EA. Meatal stenosis: A retrospective analysis of over 4000 patients. *J Pediatr Urol* 2015;11:38.e1-6. doi: 10.1016/j.jpuro.2014.09.006.
7. Dayı S, Kırılı EA, Sancar S. Is frenuloplasty a risk factor for post-circumcision meatal stenosis? *J Pediatr Urol*. 2022;18:343.e1-343.e5. doi: 10.1016/j.jpuro.2022.03.024.
8. Bazmamoun H, Ghorbanpour M, Mousavi-Bahar SH. Lubrication of circumcision site for prevention of meatal stenosis in children younger than 2 years old. *Urol J* 2008;5:233-6.
9. Upadhyay V, Hammomat HM, Pease PW. Post circumcision meatal stenosis: 12 years' experience. *N Z Med J* 1998;111:57-8.
10. Kajbafzadeh AM, Kajbafzadeh AM, Kajbafzadeh M, Arbab M, Heidari F, Arshadi HMS. Post circumcision meatal stenosis in the neonates due to meatal devascularisation: a comparison of frenular artery sparing. PlastiBell and Conventional Technique. *J Urol* 2011;185e132.
11. Frisch M, Simonsen J. Cultural background, non-therapeutic circumcision and the risk of meatal stenosis and other urethral stricture disease: Two nationwide register-based cohort studies in Denmark 1977-2013. *Surgeon* 2018;16:107-18. doi: 10.1016/j.surge.2016.11.002.
12. Shenoy SP, Marla PK, Sharma P, Bhat N, Rao AR. Frenulum sparing circumcision: Step-by-step approach of a novel technique. *J Clin Diagn Res* 2015;9:PC01-3. doi: 10.7860/JCDR/2015/14972.6860.
13. Harahap M, Siregar AS. Circumcision: A review and a new technique. *J Dermatol Surg Oncol* 1988;14:383-6. doi: 10.1111/j.1524-4725.1988.tb03371.x.
14. Lukong CS. Dorsal slit-sleeve technique for male circumcision. *J Surg Tech Case Rep* 2012;4:94-7. doi: 10.4103/2006-8808.110261.
15. Krill AJ, Palmer LS, Palmer JS. Complications of circumcision. *ScientificWorldJournal* 2011;11:2458-68. doi: 10.1100/2011/373829.
16. Dwyer ME, Salgado CJ, Lightner DJ. Normal penile, scrotal, and perineal anatomy with reconstructive considerations. *Semin Plast Surg* 2011;25:179-88. doi: 10.1055/s-0031-1281487.
17. Keegan KA, Penson DF. Vasculogenic erectile dysfunction. In: Creager MA, Beckman JA, Loscalzo J, editors. *Vascular medicine: A companion to braunwald's heart disease*. 2nd ed. Philadelphia: W.B. Saunders; 2013. p. 341-348.
18. Hinman F Jr. The blood supply to preputial island flaps. *J Urol* 1991;145:1232-5. doi: 10.1016/s0022-5347(17)38584-1.
19. Persad R, Sharma S, McTavish J, Imber C, Mouriquand PD. Clinical presentation and pathophysiology of meatal stenosis following circumcision. *Br J Urol* 1995;75:91-3. doi: 10.1111/j.1464-410x.1995.tb07242.x.
20. Sorokan ST, Finlay JC, Jefferies AL. Canadian Paediatric Society, Fetus and Newborn Committee, Infectious Diseases and Immunization Committee. Newborn male circumcision. *Paediatr Child Health* 2015;20:311-20. doi: 10.1093/pch/20.6.311.
21. Özen MA, Gündoğdu G, Taşdemir M, Eroğlu E. Are mechanical and chemical trauma the reason of meatal stenosis after newborn circumcision? *Eur J Pediatr* 2019;178:77-80. doi: 10.1007/s00431-018-3261-4.